

MORPHOLOGICAL STUDY OF POSTEROLATERAL CRANIUM & ITS IMPORTANCE IN LOCALIZING THE SAFE AREA IN NEUROSURGICAL PROCEDURES

Soniya ArunKumar Gupta¹, Nisha Goyal², Nisha Kaul³

¹Associate Professor, Anatomy, Rama Medical College, Hospital & Research Centre, Hapur, Uttar Pradesh, India.

²Professor, Anatomy, Rama Medical College, Hospital & RC Hapur, Uttar Pradesh, India.

³Professor and Head, Anatomy, Rama Medical College, Hospital & RC Hapur, Uttar Pradesh, India.

Received : 09/08/2023
Received in revised form : 16/09/2023
Accepted : 28/09/2023

Keywords:

Asterion, Posterolateral Cranium, Zygomatic Arch, Inion, Mastoid process.

Corresponding Author:

Dr. Soniya ArunKumar Gupta,
Email: gupta.soniya546@gmail.com

DOI: 10.47009/jamp.2023.5.5.312

Source of Support: Nil,
Conflict of Interest: None declared

Int J Acad Med Pharm
2023; 5 (5); 1589-1594



Abstract

Background: Neurosurgeons most commonly use Asterion as the reference point to mark a suitable and safe area on the skull for creating a burr hole to reach the cranial cavity.

Objectives: it is difficult to locate the Asterion on the skull bone. Many surface landmarks present on posterolateral cranium assist in correct marking of Asterion. **Materials and Methods:** Asterion in 30 dry skulls in the departmental bone bank were classified into type I (with Wormian bone) and type II (without Wormian bone) on both the sides. Surface landmarks on the Posterolateral craniums with type II Asterion were measured to calculate the distance from the respective Asterion. Calculations were done using Microsoft excel software. Location of Asterion was correlated with underlying venous sinuses in the hemiskulls. **Result:** 9 Asterions were classified as type I and 51 Asterion as type II. 21 (70%) Asterion were observed to be located at the junction of Transverse & Sigmoid venous sinuses. Mean distance between left and right Asterion & Inion (AI) were 6.93+/-0.35cm and 6.98+/- 0.43cm respectively. Mean distance between left and right Asterion & post end of zygomatic arch were 5.73+/- 0.27cm and 5.57+/- 0.34cm respectively. Mean distance between left and right Asterion & tip of mastoid process (AM) were 5.36+/- 0.43cm and 5.32+/- 0.37cm respectively. **Conclusion:** These measurements from the Asterion can help in locating the Asterion and will be of some help to the neurosurgeons, radiologists and anthropologists.

INTRODUCTION

Various inflammatory, vascular, neoplastic lesions are found in the posterolateral cranial fossa.^[1] The posterolateral cranium is an important anatomical region in the neurosurgery as it houses critical neurovascular structures that are vulnerable to injury during surgical procedures. The sigmoid sinus is a venous sinus that courses from the jugular foramen to the confluence of sinuses, where it merges with the transverse sinus. The transverse sinus is a paired venous sinus that runs horizontally across the posterior cranial fossa and joins the sigmoid sinus to form the jugular bulb.

The posterolateral cranium exhibits a complex morphology due to the presence of several structures that traverse this area.

The posterolateral cranium is the region located posterolateral to the external occipital protuberance and it includes various surface landmarks, the Mastoid process, Asterion, posterior root of Zygomatic arch.

Mastoid process, a conical projection, extends downwards from the lower part of mastoid part of temporal bone, behind external acoustic meatus.^[2]

Asterion is found at the junction of lambdoid, parietomastoid and occipitomastoid sutures.^[2]

The external occipital protuberance is a bony prominence located at the midline of the occipital bone that serves as an attachment point for the nuchal ligament. Most salient point of protuberance is called as Inion.^[2]

Zygomatic arch is a palpable bony landmark placed horizontally between cheek & temple. Its posterior root forms lateral boundary of mandibular fossa.

Neurosurgeons must localize appropriate point to place a burr hole, in the posterior cranial fossa, to prevent any bleeding during operative procedures on dural venous sinuses. Hence, A thorough understanding of its morphology is essential for neurosurgeons to safely navigate this area during surgical procedures. The safe area is a region that is free from major neurovascular structures and is used as a reference point for surgical navigation. The identification of the safe area in the posterolateral

cranium is essential for the safe and effective performance of surgical procedures. Neurosurgeons quite often use Asterion as important reference point for entering into the posterior cranial fossa. Many populations specific variations are found with respect to localization of Asterion.^[3]

Asterion can be localized by surrounding palpable bony landmarks. Mastoid process is a compact and easily localized palpable landmark of the skull. It can resist any kind of physical injury. Hence, it stays intact in any damaged skull.^[1] It can be used for localization of Asterion.

Finally, location of Asterion can be predicted by measuring the distance of Asterion from posterior end of Zygoma, Inion & tip of Mastoid process. Hence, this article aims to provide an overview of the measurements of Asterion from abovementioned surface landmarks of the posterolateral cranium and find out the relation of Asterion with underlying structures, in the skulls of North Indian population.

MATERIALS AND METHODS

30 Dry skulls with fused basisphenoid sutures were used for the present study from the department of Anatomy, Rama Medical College, Hospital & Research Center, Hapur.

Out of 30 skulls, 18 were hemiskulls and 12 were complete skulls.

Total 60 posterolateral cranium (on Right & Left sides) of 30 dry skulls were observed & classified into type I (with Wormian bone) & type II (without Wormian bone) on the basis of presence or absence of Wormian bone in the Asterion.

Inclusion Criteria

Intact adult hemi skulls & Complete Skulls with fused basisphenoid sutures were included in present study.

Exclusion criteria

Any abnormal or deformed skull & fetal skulls were excluded from the study. Skulls with Wormian bones in the Asterion were excluded from the measurements of various parameters in the posterolateral cranium & finding out the relation of Asterion with underlying structures.

Our study included following:

1. Measurements were performed on right & left sides (Posterolateral part of the craniums) of skulls using Vernier Calliper.

Following parameters were taken:

- Distance between Asterion (A) and Posterior end of Posterior root of Zygomatic arch (Z) - AZ
 - Distance between Asterion (A) & Tip of Mastoid Process (M)- AM
 - Distance between Asterion (A) & Inion (I) - AI
2. Relationship of Asterion with underlying structure in the Posterior Cranial Fossa was noted in 30 Posterolateral Craniums.

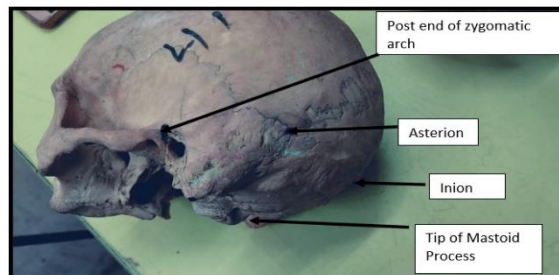


Image 1: Surface Landmarks on posterolateral cranium



Image 2: Measurement of Distance between Asterion & Inion



Image 3: Measurement of Distance between Asterion & tip of Mastoid process



Image 4: Measurement of Distance between Asterion & post end of zygomatic arch

RESULTS

In Present study, 9 posterolateral craniums (15%) were found with Wormian bones and were classified as Type I Asterion. 51 posterolateral craniums (85%) were classified as type II Asterion without Wormian bones. These 9 craniums with type I Asterion were excluded from taking measurements for various parameters.

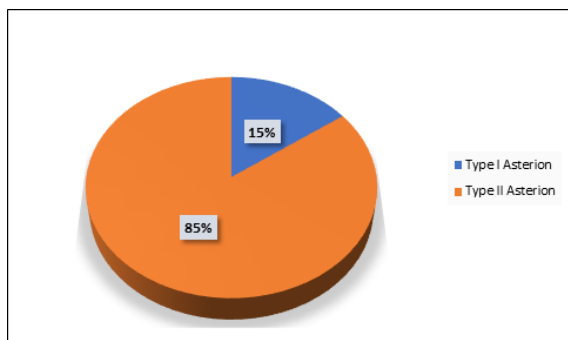


Figure 1: Classification of Asterion

[Figure 1] is a Pie chart showing that 15% of Posterolateral craniums were evaluated as Type I Asterion & 85% as Type II Asterion.

Total 51 posterolateral parts of the craniums (25 right sided & 26 left sided) were evaluated. Mean & Standard deviations were calculated. Measurements were compared on right & left side in terms of statistical significance.

Relationship of Asterion with underlying venous sinuses was noted in 30 posterolateral crania in hemiskulls.

3 (10%) Asterion were found to be against the upper border of Transverse sinuses.

21 (70%) Asterion were located at the junction of Transverse & Sigmoid venous sinuses.

6 (20%) Asterion were found to be at the lower border of Transverse sinus.




Figure 2: Average measurements on left side Posterolateral cranium

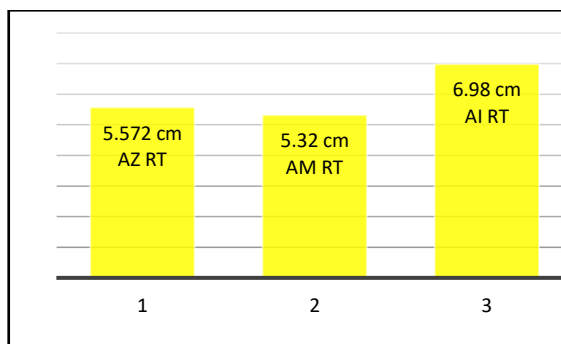


Figure 3: Average Measurement on Right Side Cranium

[Figure 2] shows the parameters on left side of posterolateral cranium. Longest distance was found between Asterion & Inion. Mean distance between left Asterion & Inion (AI) was 6.93+/-0.35cm.

Mean distance between left Asterion & left Zygomatic Arch (AZ) was 5.73+/- 0.27cm.

Shortest distance was found between Asterion & Tip of mastoid process. Mean distance between left Asterion & tip of left mastoid process (AM) was 5.36+/- 0.43cm.

[Figure 3] shows the parameters on Right side of posterolateral cranium. Longest distance was found between Asterion & Inion on both the sides. Mean distance between Right Asterion & Right Zygomatic Arch (AZ) was 5.57+/- 0.34cm. While, Asterion & tip of mastoid process was found at the shorter distance from each other on both the sides. Mean distance between right Asterion & tip of right mastoid process (AM) was 5.32+/- 0.37cm. Mean distance between right Asterion & Inion (AI) was 6.98+/- 0.43cm.

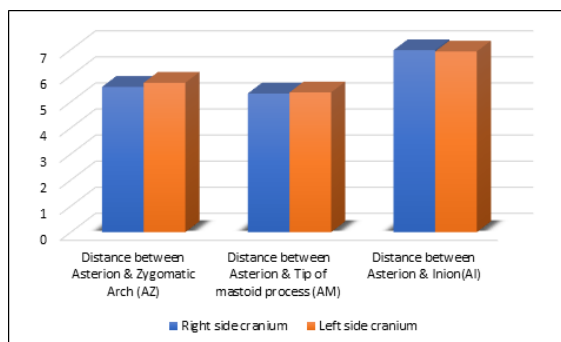


Figure 4: Comparison between Right sided & Left sided Posterolateral Cranium

As shown in [Figure 4], Distance between the Asterion & other parameters on Right & Left sides of posterolateral cranium was more or less equal.

Table 1: Measurements on posterolateral craniums

	Right side cranium	Left side cranium	P value
Distance between Asterion & Zygomatic Arch (AZ)	55.7+/- 3.4 mm	57.3+/- 2.7mm	0.0064
Distance between Asterion & Tip of mastoid process (AM)	53.2+/- 3.7mm	53.6+/- 4.3mm	0.63
Distance between Asterion & Inion (AI)	69.8+/- 4.3mm	69.3+/-3.5mm	0.35

Table 2: Comparison of the results of related studies regarding Asterion

Study done by	Asterion (A) & tip of mastoid process (M)-AM	Asterion(A) & post end of zygomatic arch(Z)- AZ	Asterion(A) & Inion (I)-AI	Type of Asterion observed	Relation of Asterion with deeper structure		
					Against the venous sinus	Above the sinus	Below the sinus
Present study	RT- 5.32 +/- 0.37 LT- 5.36 +/- 0.43	RT- 5.57 +/- 0.34 LT- 5.72 +/- 0.27	Rt- 6.98 +/- 0.43 LT- 6.93 +/- 0.34	Type I- 9 Posterolateral Cranium (15%) Type II- 51 Posterolateral cranium (85%)	70 %	10 %	20 %
PM Mwachaka et al [8]	Rt- 47.89 +/- 3.72 mm Lt- 47.62 +/- 2.87 mm	Rt -58.85 +/- 2.50 mm and Lt- 58.44 +/- 2.12 mm	NA	NA	72	1	17
Sripairojkul et al (2000) [9]	NA	NA	NA	NA	66.3%	17.4%	16.3%
Duanthongpn et al. (2016) [10]	NA	NA	NA	NA	90.9%	6.1%	3%
Hulya Ucerler et al(2006) [1]	NA	NA	NA	NA	87%	2%	11%
Wirakiat et al [11]	51.1 ± 5.3 mm.	58.3 ± 6.1 mm	62.9 ± 6.0 mm	NA	65%	10%	25%
Çalışkan S et al [15]	Rt- 5.02±0.58 mm Lt-4.87±0.56 mm	NA	NA	NA	NA	NA	NA
Lucena et al (2017) [7]	NA	NA	NA	Type I 31.67% Type II 68.33%	NA	NA	NA
Akkaşoğlu et al [12]	Rt- 45.01± 6.04mm Lt- 43.65 ± 6.75 mm	R- 43.95± 7.02 mm L- 43.97 ± 7.37 mm	R- 54.75 ± 5.57mm L- 62.59 ± 8.83 mm	NA	84%	4%	12%
Sachin et al [14]	Rt 48.77±2.23mm Lt 47.45±2.62	Rt 56.15±2.4 mm Lt 57.48±2.7 mm	NA	NA	NA	NA	NA

DISCUSSION

Present study was conducted to determine various parameters for localisation of Asterion. In Neurosurgery, the appropriate point at the beginning of craniotomy is desirable to approach into skull cavity. The Asterion is used as suitable landmark in the posterolateral region, such as the retrosigmoid approach for tumor resection in the cerebellopontine angle and the suprapetrosal approach for petrous lesions.^[4-6] Nowadays, large craniotomies can be replaced by microsurgical innovation technique, as the key-hole craniotomy to provide shorter surgery time and avoid severe complications in neurosurgery.^[6] Various surface landmarks present on skull is used to localise the Asterion. These parameters differ in different population. Hence, this study has been undertaken to get the distance between Asterion & zygomatic arch (AZ), Asterion & Mastoid process (AM), Asterion & Inion (AI) & Underlying structures are crucially correlated with surface landmarks.

If wormian bone is found at the location of Asterion, it may affect the different measurements from the Asterion & can cause confusion in the location of Asterion. Hence, Craniums with the presence of Wormian bones were excluded from taking the measurements for the localisation of Asterion. It can be classified into type I (with Wormian bones) & type II (without Wormian bones). In present study, it was observed that 15% of the Asterion were type I and type II were found in 85% of the craniums.

This finding complies with the study done by Lucena et al (2019), where the type I Asterion was 31.67 percent and type II Asterion was 68.33 percent on both side of skull.^[7] Radiologists & Neurosurgeons should keep type I Asterion in mind to prevent the misdiagnosis & Treatment.

In the Kenyan population, studied by P M Mwachaka, J Hassanali, P O Odula, position of Asterion was found at the junction of transverse & Sigmoid sinuses in 72 cases, below it in 17 cases (average 3.68 mm) and only one case had the Asterion above this junction (2.57mm).^[8]

In a study performed by Sripairojkul & Adultrakoon, in Thailand (2000), the Asterion was observed in 66.3 % cases against the venous sinuses, 16.3 % infratentorial, and 17.4 % supratentorial.^[9]

In contrast, in the study by Duanthongpon et al. (2016) the Asterion was against the venous sinuses in 90.9 % cases, located at the infratentorial position in 3 %, and at supratentorial position in 6.1 % cases.^[10]

In the study by Hulya Ucerler and Figen Govsa in (2006), The position of the Asterion has been found to be located superficial to the transverse-sigmoid sinus junction in 87% of all samples, inferior to the transverse-sigmoid sinus junction in 11% and superior to the transverse-sigmoid sinus junction in 2%.^[11]

According to, Wirakiat et al, most common location related to the Asterion was the dural venous sinuses on 65 % of tested sides, followed by infratentorial dura and supratentorial dura (25 % and 10 %) respectively.^[11]

In the study done by Akkasoglu et al, 84% of the cases Asterion was seen at the junction of transverse and sigmoid sinuses. Asterion was below the junction of transverse and sigmoid sinuses in 12% of the cases. In 4% of the cases Asterion was above the junction of transverse and sigmoid sinuses.^[12]

In Present study, performed on North Indian dry skulls, most of the Asterion (70%) are at the junction of transverse & sigmoid sinuses. Thus, it can be concluded that Asterion is most commonly located at the junction of Transverse & Sigmoid sinuses.

The transverse-sigmoid sinus junction is the most common position of the Asterion, the burr hole made directly on the Asterion, can cause injury and bleeding from the sinus.^[11]

The optimal drilling position for a retrosigmoid approach was previously suggested to be at the halfway between the mastoid apex and the Asterion.^[13] Asterion is localised using different surface landmarks present surrounding the Asterion. Thus, in present study, surrounding surface landmarks in the posterolateral cranium are measured.

P M Mwachaka et al measured Distance between the Asterion and the tip of mastoid process as 47.89 +/- 3.72 mm on the right side and 47.62 +/- 2.87 mm on the left side.^[8] Whereas Wirakiat, w.; kaewborisutsakul, a. & kankuan, k. W studied the mean distance between Asterion and Mastoid tip as 51.1 ± 5.3 mm.^[11]

Akkaşoğlu et al found Distance between Asterion and mastoid process as 43.65 ± 6.75 mm on the left side and 45.01 ± 6.04mm on the right side.^[12] Sachin et al studied posterolateral cranium in Andman & Nikobar region & found the distance between Asterion & Tip of mastoid process as 48.77 ± 2.23mm on right side & 47.45 ± 2.62mm on left side.^[13] While, Çalışkan S et al estimated the Distance between Asterion & apex of Mastoid process as 5.02 ± 0.58 cm on the right side and 4.87 ± 0.56 cm on the left side.^[14] In present study, distance between Asterion & tip of mastoid process,

were 53.2 +/- 3.7mm on right side and 53.6 +/- 4.3mm on left side of posterolateral cranium.

In a study in the Kenyan population, by P M Mwachaka, J Hassanali, P O Odula, the distances on the right and left sides from the Asterion to the root of the zygoma were 58.85 +/- 2.50 mm and 58.44 +/- 2.12 mm respectively.^[8] According to, Wirakiat et al, the mean distance between Asterion and the root of Zygomatic arch was measured as 58.3 ± 6.1 mm.^[10] Akkaşoğlu et al studied Distance between Asterion and posterior end of zygomatic arch as 43.97 ± 7.37 mm on the left side and 43.95 ± 7.02 mm on the right side.^[12] Sachin et al studied posterolateral cranium in Andman & Nikobar region & found the distance between Asterion & Zygomatic arch as 56.15 ± 2.40 mm on right side and 57.48 ± 2.68 mm on left side.^[14] In present study, distances between Asterion & post root of zygomatic arch were 55.7 +/- 3.4 mm and 57.3 +/- 2.7mm on right & left sides respectively.

Akkaşoğlu et al measured Distance between Asterion and external occipital protuberance as 62.59 ± 8.83 mm on the left side and 54.75 ± 5.57mm on the right side.^[12] Wirakiat, w.; kaewborisutsakul, a. & kankuan, k. W found the mean distance between Asterion and Inion as 62.9 ± 6.0mm.^[11]

While, in present study, Distance between Asterion & Inion (AI) were 69.8 +/- 4.3mm on right and 69.3 +/- 3.5mm on left side.

The Asterion is not a reliable point for posterolateral route and a burr hole 2 cm below the Asterion is better alternative according to Urculo E et al.^[16]

According to Çorpan et al., surgical approaches through the 10 mm superior or inferior to the Asterion have a significant risk of damaging the sigmoid and transverse sinuses.^[17]

Hence, these parameters can be of some help in finding out the safe area using Asterion as a key point in the posterolateral cranium.

CONCLUSION

The identification of the safe area in the posterolateral cranium is crucial for the safe and effective performance of surgical procedures. The landmarks and structures present in this region provide valuable information for surgical navigation and play a critical role in the localization of the safe area. Therefore, our findings may be of some help to locate suitable point for craniotomy by recognising the variation of Asterion type and its location in terms of distance from other skull landmarks and beneath structures.

REFERENCES

1. Ucerler H, Govsa F. Asterion as a surgical landmark for lateral cranial base approaches. *Journal of cranio-Maxillofacial surgery* 2006; 34: 415-420
2. Standring, S. *Gray's Anatomy: The Anatomical Basis of Clinical Practice*. 41st ed. New York, Elsevier, 2016
3. Day DJ, Kellogg JX, Tschabitscher M et al. Surface and superficial surgical anatomy of the posterolateral cranial base:

- significance for surgical planning and approach. *Neurosurg* 1996; 38(6): 1079-1084.
4. Lang Jr., J. & Samii, A. Retrosigmoidal approach to the posterior cranial fossa. An anatomical study. *Acta Neurochir. (Wien)*, 111(3- 4):147-53, 1991.
 5. Ribas, G. C. & Rodrigues, A. J. J. The suprapetrosal craniotomy. *J. Neurosurg.*, 106(3):449-54, 2007.
 6. Ribas, G. C.; Rhoton Jr., A. L.; Cruz, O. R. & Peace, D. Suboccipital burr holes and craniectomies. *Neurosurg. Focus*, 19(2):E1, 2005.
 7. Jalles Dantas de Lucena, Francisco Orlando Rafael Freitas, Italo Simoes Limeira, Thales Henrique de Araujo Sales, Joao Victor Souza Sanders, Jonathan Barros Cavalcante, Gilberto Santos Cerqueira et al. Incidence of sutural bones at asterion in dry human skulls in Northeast Brazil. *Acta Sci Anat.* 2019;1(3):178-183.
 8. P M Mwachaka , J Hassanali, P O Odula. Anatomic position of the asterion in Kenyans for posterolateral surgical approaches to cranial cavity. *Clin Anat.* 2010 Jan;23 (1):30-3.[doi:10.1002/ca.20888](https://doi.org/10.1002/ca.20888). [8]
 9. Sripairojkul, B. & Adultrakoon, A. Anatomical position of the Asterion and its underlying structure. *J. Med. Assoc. Thai.*, 83(9):1112-5, 2000. [9]
 10. Duangthongpon, P.; Thanapaisal, C.; Kitkhuandee, A.; Chaicwamongkol, K. & Morthong, V. The relationships between asterion, the transverse-sigmoid junction, the superior nuchal line and the transverse sinus in Thai cadavers: Surgical relevance. *J. Med. Assoc. Thai.*, 99 Suppl. 5: S127-31, 2016. [10]
 11. Wirakiat, w.; Kaewborisutsakul, a. & Kankuan, K. W. Anatomic position of the asterion and implication for neurosurgical procedure. *Int. J. Morphol.*, 39(5):1429-1435, 2021.
 12. Sinem Akkaşoğlu, Mine Farimaz, Hilal Akdemir Aktaş et al. Evaluation of Asterion Morphometry in Terms of Clinical Anatomy *East J Med* 24(4): 520-523, 2019 DOI: 10.5505/ejm.2019.50480
 13. Xia Y, Li XP, Han D, Zheng J, Long HS, Shi JF. Anatomic structural study of cerebellopontine angle via endoscope. *Chin Med J (Engl)* 2007;120:1836-9.
 14. Patil S et al. *Rec. Adv. Path. Lab. Med.* 2019;5(3):1719. DOI:<https://doi.org/10.24321/2454.8642.201917>
 15. Çalışkan S et al. Mastoid Process morphometry on dry skulls. *KÜ Tıp Fak Derg* 2020;22(1):58-63. Doi:10.24938/kutfd.649170
 16. Urculo E, Alfaro R, Arrazola M et al. Anatomical landmarks and surgical limits in the suboccipital transmeatal approach to the acoustic neuroma. *Neurocirugia (Astur)* 2003; 14(2): 107-115
 17. De Paiva LAS, Segre M. Sexing the human skull through the mastoid process. *Revista do Hospital das Clinicas* 2003;58:15-20